

The Modified Norwegian Method of Biceps Tenodesis

Abdullah Foad, M.D., Sami Faruqui, B.S., and Courtney C. Hanna, M.P.H.

Abstract: This technical note describes a method of biceps tenodesis called the Modified Norwegian Method that is an all-arthroscopic, intra-articular, bony biceps tenodesis that uses a suture shuttle passer through an anterosuperolateral portal. It allows for easy passage of suture through the long head of the biceps tendon while one is viewing through the posterior portal. We believe this method to be a very reasonable and simple method of biceps tenodesis that has complication rates similar to those described for subpectoral and other methods of fixation.

There are multiple ways in which the long head of the biceps tendon can contribute to anterior shoulder pain. Isolated tears of the proximal biceps tendon, subluxation or dislocation of the biceps tendon associated with or without a subscapularis tendon tear, tendinitis or tenosynovitis, and SLAP tears can contribute to anterior shoulder pain.^{1,2}

Biceps tenodesis can be effective in treating biceps tendinopathy, and several methods of tenodesis have been described including open and arthroscopic techniques. Open techniques include subpectoral fixation, suprapectoral fixation, and soft-tissue tenodesis. Arthroscopic techniques include the percutaneous intra-articular transtendon technique, interference screw fixation, and suture anchor fixation. This technical note describes another method of biceps tenodesis called the Modified Norwegian Method (MNM) that is an all-arthroscopic, intra-articular, bony biceps tenodesis that uses a suture shuttle passed with the SutureLasso passer (Arthrex, Naples, FL) through a anterosuperolateral portal. It allows for easy passage of suture through the long head of the biceps tendon while one is viewing through the posterior portal. We believe this method to be a very reasonable and simple method of biceps

tenodesis that has complication rates similar to those described for subpectoral and other methods of fixation.

Indications and contraindications for the MNM biceps tenodesis are listed in Table 1. The senior author's (A.F.) indications for biceps tenodesis were almost always related to structural damage. This included biceps subluxation due to subscapularis tendon tear or biceps pulley/sling tear, a greater than 25% tear of the biceps tendon, unstable SLAP lesions in patients aged older than 35 years, and failed previous SLAP lesion repair. Relative contraindications to biceps tenodesis include pseudoparalysis of the shoulder, glenohumeral osteoarthritis (Outerbridge grade III or IV), or rotator cuff arthropathy.

Surgical Technique

After the induction of general endotracheal anesthesia and a preoperative regional interscalene block, the patient is placed in the beach-chair position with all bony prominences well padded. The entire forequarter undergoes sterile preparation, and a marking pen is used to identify all pertinent bony landmarks. A standard posterior portal incision is made 2 cm inferior and 2 cm medial to the posterolateral corner of the acromion with a No. 11 scalpel through the skin only. An anterior working portal is made with the aid of an 18-gauge spinal needle by use of an "outside-in" technique just lateral to the coracoid tip, approaching the lesser tuberosity at a 30° to 45° angle, primarily for anchor placement. The portals are shown in Fig 1.

The glenohumeral joint is examined, and all intra-articular pathology is identified. The decision to proceed with a tenodesis is made based on the previously mentioned criteria. The superior biceps–labral anchor is tested for a positive "peel-back" sign or the appearance of greater than 5 mm of exposed superior glenoid bone, which would confirm an unstable SLAP tear.³

From the Quality Care Clinic and Surgery Center (A.F.), Clinton, Iowa; the University of Iowa Carver College of Medicine (S.F.), Iowa City, Iowa; and the University of Michigan School of Public Health (C.C.H.), Ann Arbor, Michigan, U.S.A.

The authors report that they have no conflicts of interest in the authorship and publication of this article.

Received May 31, 2013; accepted August 6, 2013.

Address correspondence to Abdullah Foad, M.D., Quality Care Clinic and Surgery Center, Clinton, IA 52732, U.S.A. E-mail: foadal@aol.com

© 2014 by the Arthroscopy Association of North America

2212-6287/13358/\$36.00

<http://dx.doi.org/10.1016/j.eats.2013.08.003>

Table 1. Indications and Contraindications

Indications: Structural Damage to LHB ⁷	Contraindications ⁷
Biceps subluxation due to subscapularis tendon tear or biceps pulley/sling tear >25% tear of LHB tendon	Pseudoparalysis of shoulder (relative)
Unstable SLAP lesion in patients aged >35 yr Failed previous SLAP lesion repair	Glenohumeral joint osteoarthritis (Outerbridge grade III or IV) Rotator cuff arthropathy (relative) Severe “lipstick biceps” (relative) “Hourglass” LHB tendon (relative) Poor quality of tendon in bicipital groove (relative)

LHB, long head of biceps tendon.

The subscapularis tendon and biceps sling are evaluated for any tear by use of the “posterior lever push” as described by Burkhart and Brady² or with the aid of a 70° arthroscope to visualize the subscapularis tendon footprint. In addition, the extra-articular portion of the biceps tendon is pulled into the joint with an arthroscopic probe to examine it.

At this time, a third anterosuperolateral portal is made by the same outside-in technique. This is placed at the level of the anterior border of the acromion and into the posterolateral aspect of the rotator interval behind the biceps tendon. If there is a rotator cuff tear, the cannula can go through the tear instead of the rotator interval. A 7-mm cannula is inserted just posterior and lateral to the biceps tendon, and a motorized 4-mm SLAP burr (Arthrex) and a 4.5-mm shaver (Arthrex) are used to prepare a fresh bleeding cortical bone bed on the humeral head just at the intra-articular entrance of the biceps tendon. This is depicted in Fig 2. Care is taken not to violate the subchondral plate. After an appropriate

bone bed is prepared, the punch for a 5.5-mm suture anchor is used through the anterior cannula at a 30° to 45° angle. A 5.5-mm BioCorkscrew double-loaded anchor (Arthrex) is inserted into the bone tunnel, as shown in Figs 3 and 4.

Next, a 25° SutureLasso (Arthrex) (left for a right-sided shoulder and right for a left-sided shoulder) is placed through the anterosuperolateral cannula and pierced through the biceps tendon in the superior-to-inferior direction at the intra-articular entrance, as shown in Fig 5. An arthroscopic grasper is brought through the anterior cannula to grasp the SutureLasso and bring it out anteriorly. By use of arthroscopic suture management, 1 of the color-coded suture limbs is placed into the SutureLasso and pulled through the joint, through the tendon, and out the anterosuperolateral cannula. The same step is repeated for another color-coded suture limb to be passed through the tendon but approximately 1 cm proximal or distal to the first suture limb so as not to potentially create a rent tear in the tendon. Next, an arthroscopic knot pusher is

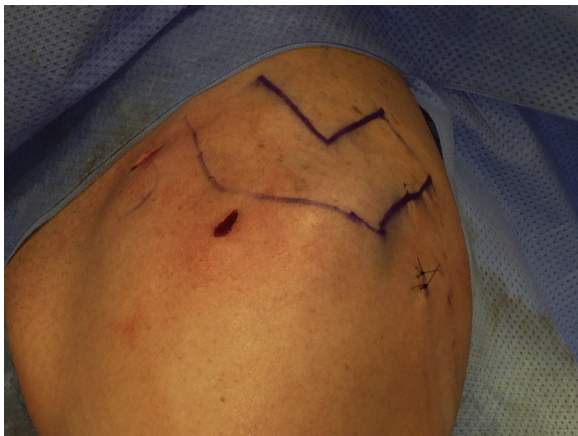

Fig 1. Portal placement (left shoulder). Placement of 3 portals is used for the MNM biceps tenodesis with the patient in the beach-chair position. Standard posterior and anterior portals, as well as an anterosuperolateral portal in line with the anterior border of the acromion coming into the posterolateral region of the rotator interval, are used. The same 3 portals may be used in conjunction with subscapularis tendon repairs and other rotator cuff tendon repairs, and they can be used with the patient in the lateral decubitus position.

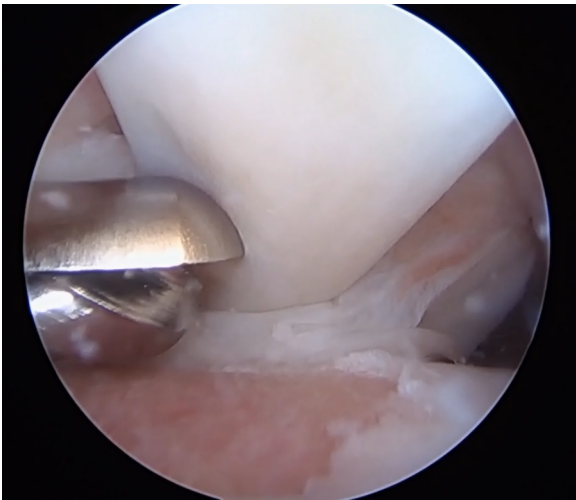

Fig 2. Preparation of bone bed (left shoulder), viewed through posterior portal. A 4.0-mm barrel burr (Arthrex) through the anterosuperolateral portal is used to create a healthy, bleeding bone bed. Care is taken not to violate the subchondral plate while protecting the tendon.

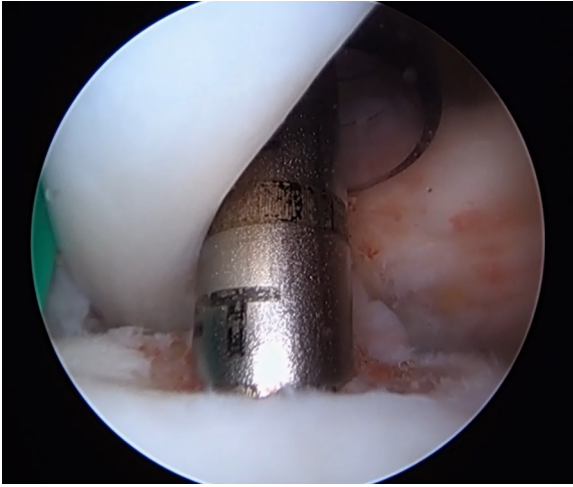


Fig 3. Tunnel placement (left shoulder), viewed through posterior portal. An Arthrex punch through the anterior portal is used to create a bony tunnel to accommodate a 5.5-mm BioCorkscrew or BioComposite Corkscrew (Arthrex).

used to push 1 suture limb that was passed through the tendon from the anterosuperolateral cannula back into the joint, superior to the tendon, and back out the anterior cannula with the aid of an arthroscopic suture grasper. The next step is to use the suture grasper through the anterosuperolateral cannula and go under the tendon to capture 1 of the free color-matched suture limbs that had not been passed through the tendon. At this point, 2 sets of color-matched sutures are present: 1 set through the anterior cannula and 1 set through the anterosuperolateral cannula. The sutures through the tendon are shown in [Fig 6](#). Arthroscopic knot tying is performed to create 2 knots

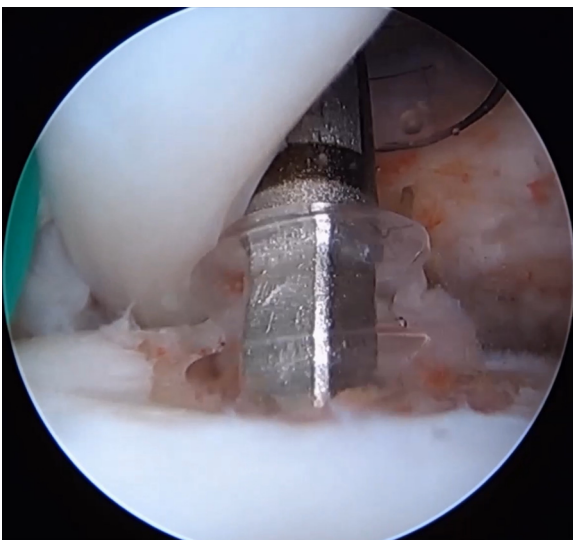


Fig 4. Anchor placement (left shoulder), viewed through posterior portal. A double-loaded 5.5-mm BioCorkscrew is placed through the anterior portal into the bone tunnel.

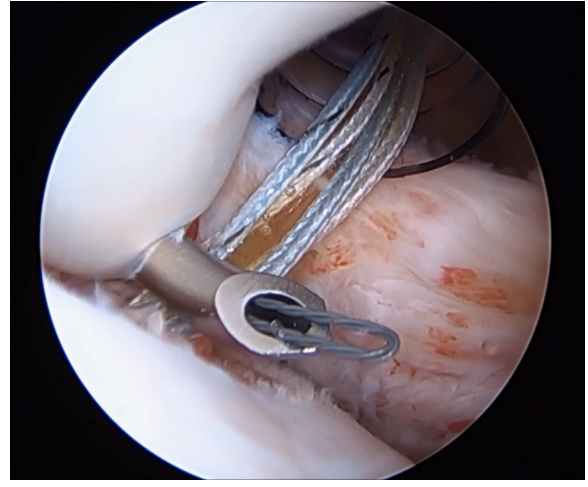


Fig 5. SutureLasso placement (left shoulder). A 25° SutureLasso (right for a left-sided shoulder and left for a right-sided shoulder) is placed through the anterosuperolateral cannula and pierced through the biceps tendon in the superior-to-inferior direction at the intra-articular entrance.

allowing double fixation, 1 medial and 1 lateral to the tendon, thus laying the tendon flat onto the bone bed to maximize tendon-bone surface area. During this procedure, the elbow is resting at approximately 20° to 30° of flexion. Finally, an arthroscopic scissor or meniscal biter is used to perform the tenotomy proximal to the 2 suture knots. The remaining proximal

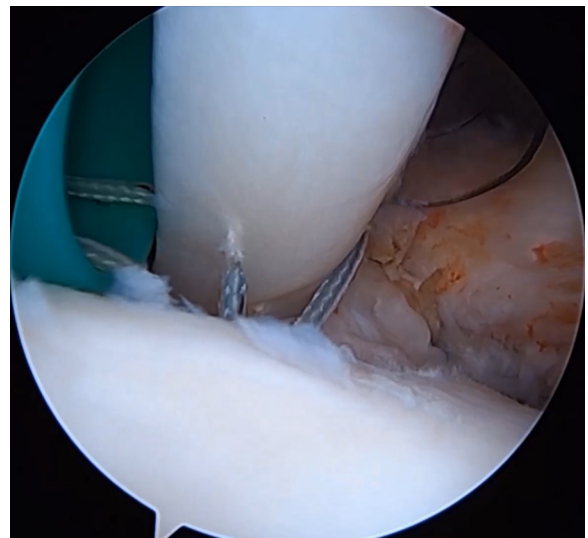


Fig 6. Suture through tendon (left shoulder), viewed through posterior portal. By use of arthroscopic suture management, 1 of the color-coded suture limbs is placed into the SutureLasso and pulled through the joint, through the tendon, and out the anterosuperolateral cannula. The same step is repeated for another color-coded suture limb to be passed through the tendon but approximately 1 cm proximal or distal to the first suture limb so as not to potentially create a rent tear in the tendon.

biceps remnant is debrided to a stable biceps-labral stump. The most important aspects of the MNM technique are shown in [Video 1](#).

The rehabilitation program for the MNM biceps tenodesis is outlined in [Table 2](#). Postoperative management specific to our biceps tenodesis technique includes shoulder immobilization for 4 to 6 weeks. During this time, there is no active flexion or extension of the arm because this can weaken the fixation of the biceps tendon. Passive flexion of the arm and pendulum exercises are encouraged 2 to 3 times per day. The patient is allowed active motion of the wrist and hand. Passive motion is increased by the physical therapist as tolerated in a controlled setting. The patient may begin active and active-assisted range of motion at 6 weeks. Pulley exercises may be initiated at 8 weeks because earlier use of pulleys has been noted to irritate the biceps. Strengthening begins at 10 to 12 weeks depending on concomitant surgeries. Unrestricted activities can resume as early as 4 months.

Discussion

When a surgeon decides to perform a biceps tenodesis, a decision must be made whether to perform tenodesis proximal or distal to the bicipital groove. Although there is controversy in the literature with regard to proximal or distal tenodesis, the pain generated from the biceps tendon is likely due to abnormal motion from structural damage. Performing a tenodesis, whether proximal or distal, will remove the pathologic motion between the tendon and the bicipital groove and remove the source of impingement in the glenohumeral joint.

Currently, there are no high-level, prospective, randomized data that compare different tenodesis techniques for the long head of the biceps tendon with regard to their clinical and structural results. We find our method of arthroscopic biceps tenodesis to have several advantages over other described methods of biceps tenodesis. First, it allows us to perform an osseous

fixation biceps tenodesis, which has been shown to be superior to soft-tissue tenodesis, while still performing the operation entirely arthroscopically.⁴ Second, in the MNM the surgeon performs tenodesis of the biceps in an anatomic position without having to worry about proper tensioning or resting length as would have to be taken into account with other open or arthroscopic techniques. With other arthroscopic suprapectoral methods, the surgeon has to bring the long head of the biceps tendon out of the shoulder and through the anterior portal to place sutures, calculate the proper length-tension relation, and then navigate the tendon back into the shoulder, which can be a struggle.⁵ In addition, the same 3 portals used for the MNM can be used to proceed with repair of the subscapularis tendon and other rotator cuff tendons without having to make extra open incisions. Third, after tenodesis, the final construct removes the long head of the biceps from its intra-articular course, which may be the source of impingement or pain while concurrently helping to prevent adhesion formation as seen in the open or mini-open approach. We also believe that our modified approach is improved because the original Norwegian technique used a double-loaded sharp-tipped metal corkscrew anchor that pierced through the tendon. Although this lessened the suture management steps, it created a larger hole in the tendon that could potentially increase suture cutout, biceps failure, or rupture from the tenodesis site.

There are disadvantages, limitations, and risks with the described procedure that should be noted, however. Failure of fixation and persistent bicipital pain are the most commonly reported complications with this technique; however, these are the same common complications described with the open subpectoral biceps tenodesis described by Arora et al.⁶ In addition, this is not considered an “intraosseous” tenodesis. Theoretically, this could be a weaker method of biomechanical fixation.⁷ This method also depends on a healthy biceps tendon to be able to hold the sutures. If the rotator interval is too small, it may be necessary to repair the anterior fibers of the supraspinatus tendon after placement of the anterosuperolateral portal. There is also potential for placing suture knots against the articular surface of the humeral head. Another risk is potentially unloading the suture anchor. Although this is not unique to this method, we recommend paying attention to the suture limbs during suture management.

Overall, success in the MNM is dependent on a well-performed surgery, addressing all pathology in the shoulder correctly and proper rehabilitation of patients. We believe this method to be a very reasonable and simple approach to the damaged biceps tendon that results in good subjective clinical outcomes including predictable pain relief that can be achieved with an all-arthroscopic technique.

Table 2. Rehabilitation

	Description
0-6 wk	Shoulder immobilization PROM of elbow, 0°-140° Pendulum exercises 2-3 times per day AROM of wrist and hand PROM of shoulder by PT as tolerated in controlled setting
6-8 wk	A/AROM
8 wk	Pulley exercises
10-12 wk	Strengthening biceps depending on concomitant procedures
4 mo	Unrestricted activities

AROM, active range of motion; A/AROM, active assistive range of motion; PROM, passive range of motion; PT, physical therapist.

References

1. Alpantaki K, McLaughlin D, Karagogeos D, Hadjipavlou A, Kontakis G. Sympathetic and sensory neural elements in the tendon of the long head of the biceps. *J Bone Joint Surg Am* 2005;87:1580-1583.
2. Burkhart SS, Brady PC. Arthroscopic subscapularis repair: Surgical tips and pearls A to Z. *Arthroscopy* 2006;22:1014-1027.
3. Morgan CD, Burkhart SS, Palmeri M, Gillespie M. Type II SLAP lesions: Three subtypes and their relationships to superior instability and rotator cuff tears. *Arthroscopy* 1998;14:553-565.
4. Scheibel M, Schröder RJ, Chen J, Bartsch M. Arthroscopic soft tissue tenodesis versus bony fixation anchor tenodesis of the long head of the biceps tendon. *Am J Sports Med* 2011;39:1046-1052.
5. Denard PJ, Dai X, Hanypsiak BT, Burkhart SS. Anatomy of the biceps tendon: Implications for restoring physiological length-tension relation during biceps tenodesis with interference screw fixation. *Arthroscopy* 2012;28:1352-1358.
6. Arora AS, Singh A, Koonce RC. Biomechanical evaluation of a unicortical button versus interference screw for sub-pectoral biceps tenodesis. *Arthroscopy* 2013;29:638-644.
7. Mazzocca AD, Bicos J, Santangelo S, Romeo AA, Arciero RA. The biomechanical evaluation of four fixation techniques for proximal biceps tenodesis. *Arthroscopy* 2005;21:1296-1306.