The modified Norwegian method of biceps tenodesis: how well does it work?

Sami Faruqui, Mohammad A. Kotob, Courtney C. Hanna & Abdullah Foad

Knee Surgery, Sports Traumatology, Arthroscopy

ISSN 0942-2056

Knee Surg Sports Traumatol Arthrosc
DOI 10.1007/s00167-016-4145-7

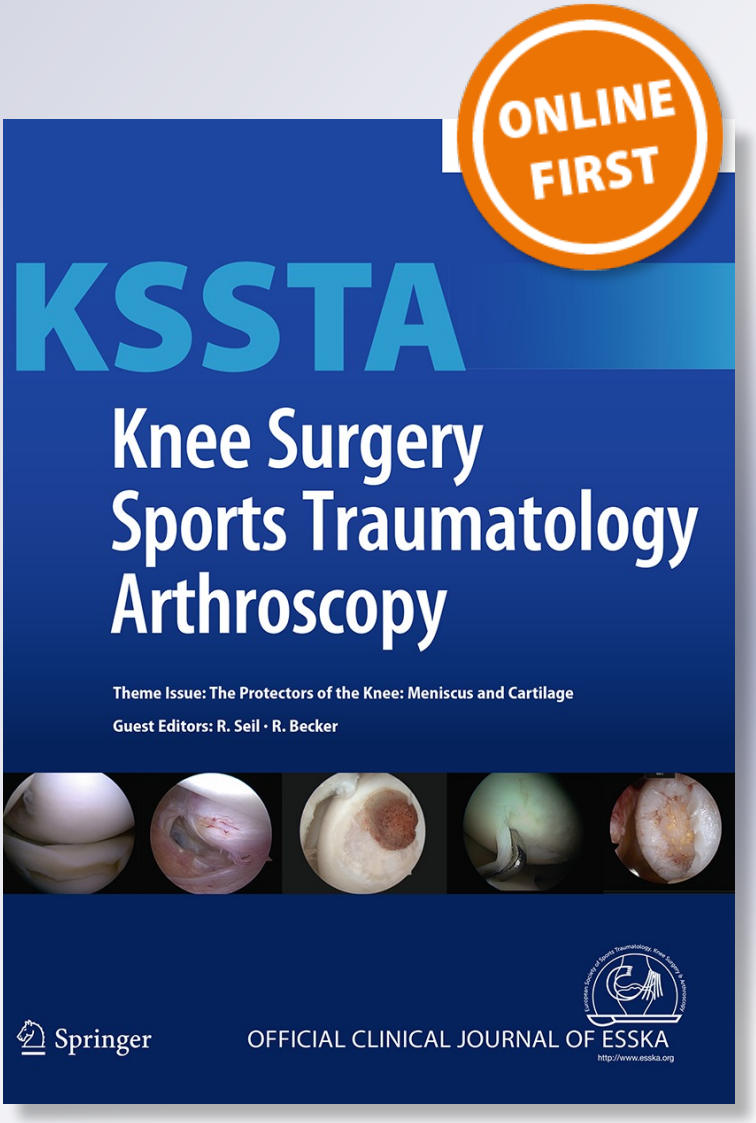

Knee Surg Sports Traumatol Arthrosc
DOI 10.1007/s00167-016-4145-7

SHOULDER

The modified Norwegian method of biceps tenodesis: how well does it work?

Sami Faruqui[1] · Mohammad A. Kotob[2] · Courtney C. Hanna[3] · Abdullah Foad[4]

Received: 10 December 2015 / Accepted: 20 April 2016

Abstract
Purpose The purpose of this study was to evaluate clinical outcomes and complications in a series of patients who underwent the modified Norwegian method (MNM) of biceps tenodesis by a single shoulder surgeon.
Methods A retrospective review of charts from all patients who underwent the modified Norwegian method of biceps tenodesis by the senior author during a 5-year period between 2008 and 2013 was performed. After all patients were identified, informed consent was obtained and DASH and ASES surveys were administered. Inclusion criteria for the study were a minimum 2-year follow-up after MNM tenodesis and appropriate adherence to DASH and ASES survey protocol. Data obtained included: demographic data, time to follow-up, hand dominance, concomitant procedures, workman's compensation (WC) status, DASH and ASES surveys, and complications. A complication was defined as rupture of the tenodesis or post-operative infection. Residual shoulder pain was considered as treatment failure. The data were then analysed using statistical software. In this time period, 94 biceps tenodeses using the MNM technique were performed. Follow-up rate was 75/94 patients (80 %). Of 75 patients, 15 (20 %) had an isolated tenodesis performed.
Results There was no statistically significant difference in DASH or ASES scores when comparing isolated tenodesis patients to those who had concomitant procedures. WC patients had worse DASH and ASES scores ($p = 0.016$; $p = 0.002$). The complication rate was 2/75 (3 %), which were both ruptured tenodeses. Of 75 patients, 3 (4 %) experienced treatment failure with residual anterior shoulder pain.
Conclusions There is debate in the literature regarding the optimal method of biceps tenodesis. This paper demonstrates that the MNM tenodesis appears to be a simple, efficient, and effective alternative to other methods of biceps tenodesis with subjective outcome scores and complication rates that parallel other methods previously described in the literature.
Level of evidence IV.

Keywords Shoulder · Biceps tenodesis · Arthroscopy · Biceps · Long head of the biceps

Introduction

It is uncertain what the exact function of the long head of the biceps tendon (LHBT) really is. Some studies suggest that it acts as a passive stabilizer that can take on the role of a humeral head suppressor in the presence of rotator cuff deficiency, while others regard it to be nothing more than a vestigial structure [9, 11]. Anterior shoulder pain is often seen with tears of the LHBT, tendinitis or tenosynovitis, and superior labrum anterior-to-posterior (SLAP) tears [1, 16]. Injury to the LHBT is often associated with full-thickness rotator cuff tears and can lead to anterior shoulder pain, which can lead to difficulty with forward flexion [12].

IRB approval obtained from UnityPoint Trinity in Moline, IL, USA.

✉ Sami Faruqui
sami-faruqui@uiowa.edu

1 Department of Radiology, University of Iowa, 200 Hawkins Drive, Iowa City, IA 52246, USA

2 Carver College of Medicine, University of Iowa, Iowa City, IA, USA

3 Penn State College of Medicine, Hershey, PA, USA

4 Quality Care Clinic and Surgicenter, Clinton, IA, USA

Published online: 03 May 2016

The two most common surgical methods to address biceps tendon pathology that is refractive to non-operative management are biceps tenotomy and tenodesis. However, there are no data that definitively identify which of these interventions is superior [4]. There is some literature that suggests they may have similar functional outcomes, although tenotomy is more frequently associated with cosmetic deformity. Several methods of arthroscopic and open tenodesis have been described and evaluated in the literature. Recently, a new all-arthroscopic, intra-articular, bony tenodesis called the modified Norwegian method (MNM) of biceps tenodesis was described [3]. This new technique allows the arthroscopist to perform an osseous fixation tenodesis using the same three portals used for concomitant subscapularis, supraspinatus, and infraspinatus tendon repairs. The indications for the MNM biceps tenodesis were almost always related to structural damage. This included biceps subluxation due to subscapularis tendon tear or biceps pulley/sling tear, a greater than 25 % tear of the biceps tendon, unstable SLAP lesions in patients aged older than 35 years, and failed previous SLAP lesion repair. Relative contraindications to biceps tenodesis included pseudoparalysis of the shoulder, glenohumeral osteoarthritis (Outerbridge grade III or IV), severe "lipstick" biceps tenosynovitis, "hour-glass" biceps tendon, poor quality of tendon in the bicipital groove, or rotator cuff arthropathy. As the MNM tenodesis is a proximal tenodesis, patients with more distal LHBT pathology would not be optimal candidates for the MNM tenodesis, and thus, these patients were excluded.

The purpose of this study was to evaluate clinical outcomes and complications in a series of patients who underwent this procedure by a single shoulder surgeon. The hypothesis of this study was that the MNM tenodesis would have good clinical outcomes and a low complication rate similar to other methods previously described. It was also hypothesized that workman's compensation (WC) patients may have worse subjective outcomes than non-WC patients.

Materials and methods

A retrospective review of charts from all patients who underwent MNM biceps tenodesis in a 5-year period by the senior author was performed. After IRB approval was obtained, all patients were identified, informed consent was obtained, and DASH and ASES surveys were administered, either online, by phone, or on paper, depending on participant preference. Inclusion criteria for the study were a minimum 2-year follow-up after MNM tenodesis and appropriate adherence to DASH and ASES survey protocol. All patients who participated appropriately adhered to survey protocol.

Table 1 Participant characteristics ($n = 75$)

Characteristic	Percent (unless otherwise noted)
Age in years, mean (S.E)	54.9 (11.0)
Gender	
Male	78.7
Female	21.3
Follow-up time, mean (S.E)[a]	3.9 (1.1)
DASH score, mean (S.E)	11.9 (16.4)
ASES score, mean (S.E)	81.1 (21.8)
Tenodesis procedure only	20.0
Ruptured	2.7
Anterior arm pain	4.0
Workman's compensation	33.3

[a] Measured in years

Data obtained included: demographic data, time to follow-up, hand dominance, concomitant procedures, WC status, DASH and ASES surveys, and complications. Demographic data are summarized in Table 1. A complication was defined as rupture of the tenodesis or post-operative infection, and treatment failure was defined as the presence of residual anterior shoulder pain. Between 2008 and 2013, the senior author performed 94 biceps tenodeses using the MNM technique. Follow-up survey data were available for 75/94 patients (80 %). Eighteen patients were unable to be reached, and one patient was deceased. Of 75 patients, 15 (20 %) had an isolated tenodesis performed.

Institutional review board approval was obtained through the UnityPoint Health Trinity IRB (Moline, IL, USA; FWA 00002702; IORG 0001972).

Surgical technique

The procedure is viewed entirely from a standard posterior portal while working through both an anterior and an anterosuperolateral portal. Seven millimetre (mm) cannulas are placed in the two portals. Next, a 4-mm arthroscopic bur and shaver are used to lightly decorticate a small area on the humeral head at the intra-articular aperture of the LHBT. Care is taken not to violate the subchondral plate. A bone punch is used to create a tunnel for a 5.5-mm suture anchor placed through the anterior portal at a 30°–45° angle. A 5.5-mm Biocomposite Corkscrew (Arthrex, Inc., Naples, FL) double-loaded anchor is inserted into the created bone tunnel.

Suture management begins next using a 25-degree suture lasso (Arthrex, Inc., Naples, FL) (left sided for a right shoulder and right sided for a left shoulder) through the anterosuperolateral portal and passing through the mid-substance of the LHBT near its aperture from a superior to inferior direction. The passing wire is brought out the

anterior portal, and one colour-matched and another colour-matched suture limb are placed through it and retrieved back into the joint, through the LHBT and out the anterosuperolateral portal. Two passes can be made 1 cm apart bringing one suture limb at a time as another option to secure the LHBT over more surface area on the prepared bone bed. Subsequently, an arthroscopic knot pusher is used to pass one of the post-suture limbs back through the anterosuperolateral portal, over the LHBT, and out through the anterior portal with the aid of a suture grasper. The next step is to bring the suture grasper through the anterosuperolateral portal, under the LHBT to retrieve one of the free colour-matched suture limbs (not passed through the tendon). Now, two sets of colour-matched suture limbs are ready for arthroscopic knot tying: one set through the anterior cannula and the other through the anterosuperolateral cannula. Figure 1 depicts the arthroscopic approach, suture management, and anatomy of the tenodesis. Two knots one on each side of the LHBT are created to secure the LHBT flat onto the bone bed in order to maximize the tendon–bone contact surface area. The elbow is kept at 20–30 degrees of flexion during knot tying as this is the resting position of the arm in the beach-chair position. The final step is to perform a tenotomy proximal to the two suture knots and debride the proximal biceps remnant to a stable stump. Figure 2 demonstrates the completed tenodesis.

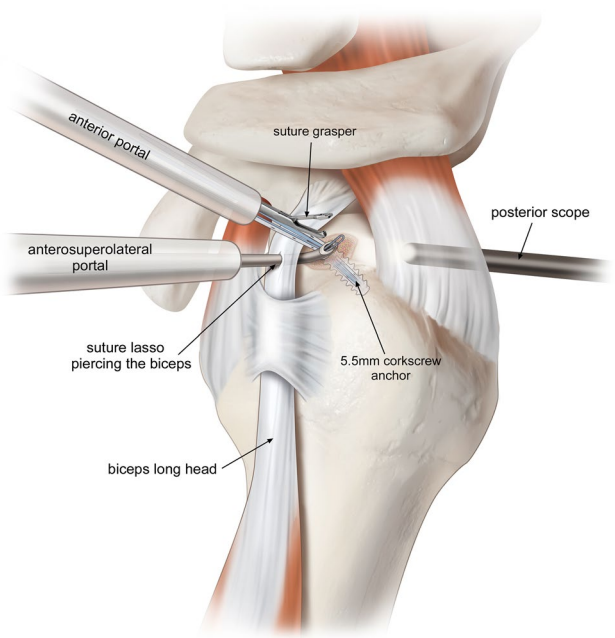

Fig. 1 Anchor placement and suture management (left shoulder drawing), viewed through posterior portal. A double-loaded 5.5-mm Biocomposite Corkscrew is placed through the anterior portal into the prepared bone tunnel. A 25° SutureLasso (right for a left-sided shoulder and left for a right-sided shoulder) is placed through the anterosuperolateral cannula and pierced through the biceps tendon in the superior-to-inferior direction at the intra-articular entrance

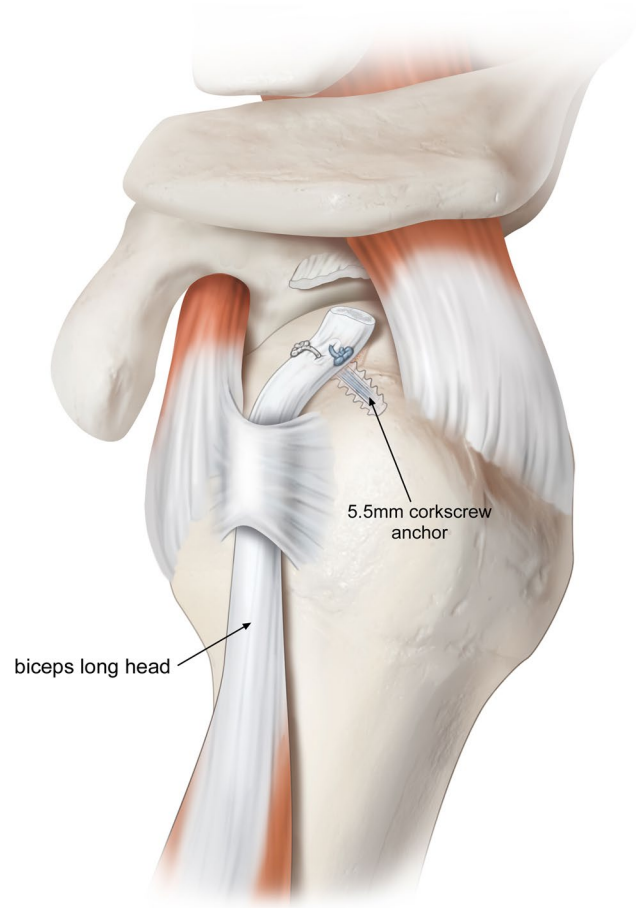

Fig. 2 Final construct (left shoulder drawing). Two color-coded sutures placed approximately 1 cm apart so as not to potentially create a rent tear in the tendon. The tendon is released from the biceps/labral attachment after the tenodesis

Statistical analysis

After survey data were obtained, the data were analysed using SPSS version 21. During analysis, patients were split into WC versus non-WC groups as well as isolated tenodesis versus tenodesis with concomitant procedures groups. Because the data were not normally distributed, the differences in mean DASH and ASES scores were assessed using the Wilcoxon rank-sum test (Mann–Whitney U test) for non-normally distributed data. The median values for scores are reported rather than ranks for ease of interpretability. Complications among WC versus non-WC groups were normally distributed and assessed using a Chi-square test. A two-tailed statistical power analysis was then performed using the respective means, standard deviations, and sample sizes. When comparing WC groups to non-WC

Table 2 Outcomes following surgery

ASES scores	WC = 73.4	Non-WC = 95.9	$p = 0.002$
	Isolated tenodesis = 66.7	Tenodesis with concomitant procedures = 92.5	n.s.
DASH score	WC = 10.0	Non-WC = 2.5	$p = 0.016$
	Isolated tenodesis = 9.2	Tenodesis with concomitant procedures = 3.3	n.s.

Median values reported

Table 3 Complications following surgery

	WC	Non-WC	
Anterior arm pain	1/25 (4 %)	2/50 (4 %)	n.s.
Rupture	2/25 (8 %)	0/50 (0 %)	n.s.

groups, the statistical power for ASES and DASH scores was 86.8 and 84.3 %, respectively. The statistical power for ASES and DASH scores when comparing the group with isolated tenodeses to the group with concomitant procedures was 57.1 and 36.3 %, respectively.

Results

Outcome score data are described in Table 2. Specifically, WC patients had worse DASH and ASES scores ($p = 0.016$; $p = 0.002$). There was no statistically significant difference in DASH or ASES scores when comparing isolated tenodesis patients to those who had concomitant procedures.

Among the patients for whom survey data were available, there was a total of 2/75 (3 %) complications, both of which were tenodesis ruptures. There were 3 patients with residual anterior arm pain signifying treatment failure. One of the patients with anterior arm pain had resolution of symptoms within 4.5 months, one was converted to an open subpectoral tenodesis, and one underwent a second-look arthroscopy showing a healed biceps tenodesis but was converted to a tenotomy. Both patients who had rupture of the tenodesis were WC patients. There were no complications with the 15 isolated MNM tenodesis cases (Table 3).

Discussion

The most important finding of this study was that the MNM tenodesis has outcome scores and complication rates similar to other techniques of biceps tenodesis. Although there are several options for treatment for LHBT pathology, biceps tenodesis is commonly the option that is chosen. Theoretically, removing the pathologic motion between the intertubercular groove and the LHBT by tenodesing the tendon should alleviate the impingement. There are several methods of performing the tenodesis that differ in both location and mechanism of fixation, but the optimal location of fixation of the LHBT is debated in the literature. To the authors' knowledge, there is currently an absence of high-level prospective data comparing different methods of tenodesis. From a biomechanical standpoint, the integrity of LHBT fixation has been studied. Although interference screw fixation was found to be superior to suture anchors at time zero, another study showed no significant difference between failure loads for the first nine weeks [8, 13]. Mazzocca et al. [10] showed that ultimate failure was statistically equivalent among subpectoral interference screw (open), arthroscopic interference screw, and suture anchor.

A summary of the results from several studies evaluating biceps tenodesis including this one can be found in Table 4. Currently, the largest study is one published by Brady et al. in 2014 [2]. Of their 1083 patients who underwent arthroscopic proximal biceps tenodesis, a mere 0.4 % experienced a rupture. Although DASH and ASES data were not collected, there was a significant improvement in other outcome scores. Werner et al. [19] and Gombera et al. [5] demonstrated no statistically significant difference in ASES scores between groups of patients who underwent open subpectoral and arthroscopic suprapectoral tenodeses. Kany et al. [7] evaluated 123 patients who underwent arthroscopic keyhole biceps tenodesis, and the rate of rupture in this group was 18.5 %. Arthroscopic soft tissue biceps tenodesis has also been described in the literature, but MRI evidence of tenodesis failure has been seen in up to 75 % of cases [15]. Su et al. [18] recently presented a method of biceps tenodesis in which LHB tenotomy is performed arthroscopically; however, this is followed by a traditional, open subpectoral biceps tenodesis, which differs from the MNM.

When compared to what has been previously reported in the literature, it appears that the MNM tenodesis has comparable outcomes. ASES scores for patients who have had biceps tenodesis appear to be consistently in the upper 80s. In this study, the average ASES was 81.1. Although this is slightly lower than seen in other studies, this is also the only study known to the authors that separates outcomes of WC patients versus non-WC patients. Of 75 patients, 25 (33 %) in our study were WC patients. The median ASES score for WC patients was 73.4, while the median for non-WC patients was 95.9 ($p = 0.002$). The average ASES

Table 4 Summary of tenodesis outcomes in the literature

Authors	#	Type of tenodesis	Rupture rate	Shoulder pain rate	DASH	ASES	Other outcome score
Brady et al.	1083	Arthroscopic proximal	0.4 %	0 %	N/A	N/A	83 % improvement VAS, 102 % improvement SST
Gottschalk et al.	36	Open subpectoral	3 %	Improved VAS but unreported	N/A	87.5	N/A
Werner et al. [19]	32	Arthroscopic suprapectoral	0 %	9.4 %	N/A	90.1	90.7 constant, 87.4 SANE, 10.4 SST
Werner et al. [19]	50	Open subpectoral	0 %	6 %	N/A	88.4	91.8 constant, 87 SANE, 10.6 SST
Kany et al.	123	Keyhole arthroscopic	18.5 %	0 %	N/A	N/A	N/A
Gupta et al.	28	Open subpectoral	Not reported	Not reported	N/A	89	68 % improvement SST, 61 % improvement SANE, 71 % improvement VAS
Gombera et al.	46	Half arthroscopic suprapectoral, half open subpectoral	0 %	35, 43 %	N/A	88.9, 92.3	N/A
Faruqui et al.	52	MNM	3 %	4 %	11.9	81.1	N/A

score in individuals with no shoulder pathology has been reported to be in the low 90s [14]. Although there is no control group for this study or the studies seen in Table 4, there may or may not be any statistically significant difference in ASES scores between patients having undergone MNM tenodesis and athletes with no shoulder pathology, but this would need to be studied further. Regarding complications, the complication rate in this study was 2/75 (3 %). Only 3/75 (4 %) had residual shoulder pain at the time of follow-up. Both of the ruptures in this case were WC patients. One of them described a traumatic rupture from a fall, and the other stated that he tore it by stretching too hard during physical therapy. It appears that the complication rate in this study is similar to that described in the literature for other methods of bony LHBT tenodesis, which has been reported to be anywhere from less than 1 to 18.5 % [2, 7].

There are some advantages to the proximal intra-articular all-arthroscopic bony MNM tenodesis versus other methods of tenodesis. First, it is possible to perform an osseous fixation, which has been shown to be superior to soft tissue tenodesis [8, 15]. Hussain et al. [6] provide an excellent overview of LHBT anatomy in the context of biceps tenodesis. However, by performing a proximal intra-articular all-arthroscopic bony tenodesis as in the MNM technique, the surgeon can avoid the worries of proper tensioning or resting length. It is also possible to obtain an osseous tenodesis, avoid injury to the axillary nerve branches, remove the LHB from its intra-articular course, which may be the source of impingement or pain, and concurrently help to prevent adhesion formation because the surgeon has good visualization as in the open or mini-open approach. In addition, the same 3 portals used for the MNM can be used to proceed with repair of the subscapularis tendon and other rotator cuff tendons without having to make extra portals or convert to an open incision, which may be of interest to patients. Sperling et al. [17] reported in a two-centre prospective survey that 88–96 % of patients prefer the idea of arthroscopic shoulder surgery over open shoulder surgery and 14–25 % of respondents stated that they would avoid surgery if the only option was open shoulder surgery. Secondly, in the MNM, the biceps tendon is fixated in an anatomic position with no need to extract the tendon exteriorly or worry about the length–tension relationship. Thirdly, with failure rates comparable to or better than that seen with open techniques, the MNM may be a reasonable alternative. The modified approach may be improved as the original Norwegian technique used a double-loaded sharp-tipped metal corkscrew anchor (Smith & Nephew, Memphis, TN) that pierced through the tendon which lessened the suture management steps. Creating a larger hole in the tendon could potentially increase suture cut-out or biceps failure or rupture from the tenodesis site, but this has not been studied thoroughly.

There are limitations in this study that should be noted. In addition, there are some limitations to the MNM, which have been previously described [3]. There were some complications from the procedure, although the incidence does not appear to be different than that of other techniques. This is a retrospective analysis, which is not as powerful as a prospective study. The sample size is also limited with a follow-up rate of 80 %, as the rural nature of the community made communication difficult at times. Due to the small sample size of patients with isolated tenodeses, statistical power was low when comparing the isolated tenodesis group to the tenodesis with concomitant procedure group.

Preoperative DASH and ASES scores were not obtained so it is not possible to objectively comment on improvement post-operatively, but it is assumed that the favourable DASH and ASES scores are a result of the biceps tenodesis and other concomitant procedures in some cases. There was no control group with which to compare outcome scores, but outcome data were compared to other previously published studies. However, it should be noted that comparing our retrospective study with other prospective or retrospective studies may be of limited value. The true incidence of LHBT ruptures is not known as the only ones that were confirmed were symptomatic patients that returned.

As mentioned previously, there are several ways to address pathology of the LHBT. The MNM tenodesis is a simple technique which allows the operator to perform an osseous tenodesis through the same three portals used for other arthroscopic procedures. It appears to have similar outcomes to other techniques previously described and as such may be a viable alternative for shoulder surgeons who treat LHBT pathology.

Conclusion

The MNM tenodesis appears to be a simple, efficient, and effective alternative to other methods of biceps tenodesis with subjective outcome scores and complication rates that parallel other methods previously described in the literature.

Acknowledgments The authors would like to thank the Iowa Orthopaedic Research Foundation for their support.

References

1. Alpantaki K, McLaughlin D, Karagogeos D, Hadjipavlou A, Kontakis G (2005) Sympathetic and sensory neural elements in the tendon of the long head of the biceps. J Bone Joint Surg Am 87(7):1580–1583
2. Brady PC, Narbona P, Adams CR, Huberty D, Parten P, Hartzler RU, Arrigoni P, Burkhart SS (2015) Arthroscopic proximal biceps tenodesis at the articular margin: evaluation of outcomes, complications, and revision rate. Arthroscopy 31(3):470–476
3. Foad A, Faruqui S, Hanna CC (2013) The modified Norwegian method of biceps tenodesis. Arthrosc Tech 3(1):e1–e5
4. Frost A, Zafar MS, Maffulli N (2009) Tenotomy versus tenodesis in the management of pathologic lesions of the tendon of the long head of the biceps brachii. Am J Sports Med 37:828–833
5. Gombera MM, Kahlenberg CA, Nair R, Saltzman MD, Terry MA (2015) All-arthroscopic suprapectoral versus open subpectoral tenodesis of the long head of the biceps brachii. Am J Sports Med 43(5):1077–1083
6. Hussain WM, Reddy D, Atanda A, Jones M, Schickendantz M, Terry MA (2015) The longitudinal anatomy of the long head of the biceps tendon and implications on tenodesis. Knee Surg Sports Traumatol Arthrosc 23(5):1518–1523
7. Kany J, Guinand R, Amaravathi RS, Alassaf I (2015) The keyhole technique for arthroscopic tenodesis of the long head of the biceps tendon. In vivo prospective study with a radio-opaque marker. Orthop Traumatol Surg Res 101(1):31–34
8. Kilicoglu O, Koyuncu O, Demirhan M, Esenyel CZ, Atalar AC, Ozsoy S, Bozdag E, Sunbuloglu E, Bilgic B (2005) Time-dependent changes in failure loads of 3 biceps tenodesis techniques: in vivo study in a sheep model. Am J Sports Med 33(10):1536–1544
9. Lippmann RK (1944) Bicipital tenosynovitis. N Y State J Med 90:2235–2241
10. Mazzocca AD, Bicos J, Santangelo S, Romeo AA, Arciero RA (2005) The biomechanical evaluation of four fixation techniques for proximal biceps tenodesis. Arthroscopy 21(11):1296–1306
11. McGough RL, Debski RE, Taskiran E, Fu FH, Woo SL (1996) Mechanical properties of the long head of the biceps tendon. Knee Surg Sports Traumatol Arthrosc 3(4):226–229
12. Murthi AM, Vosburgh CL, Neviaser TJ (2000) The incidence of pathologic changes of the long head of the biceps tendon. J Shoulder Elbow Surg 9(5):382–385
13. Richards DP, Burkhart SS (2005) A biomechanical analysis of two biceps tenodesis fixation techniques. Arthroscopy 21(7):861–866
14. Sallay PI, Reed L (2003) The measurement of normative American Shoulder and Elbow Surgeons scores. J Shoulder Elbow Surg 12(6):622–627
15. Scheibel M, Schröder RJ, Chen J, Bartsch M (2011) Arthroscopic soft tissue tenodesis versus bony fixation anchor tenodesis of the long head of the biceps tendon. Am J Sports Med 39(5):1046–1052
16. Snyder SJ, Karzel RP, Del Pizzo W et al (1990) SLAP lesions of the shoulder. Arthroscopy 26(8):274–279
17. Sperling JW, Smith AM, Cofield RH, Barnes S (2007) Patient perceptions of open and arthroscopic shoulder surgery. Arthroscopy 23(4):361–366
18. Su WR, Ling FY, Hong CK, Chang CH, Lin CL, Jou IM (2015) Subpectoral biceps tenodesis: a new technique using an all-suture anchor fixation. Knee Surg Sports Traumatol Arthrosc 23(2):596–599
19. Werner BC, Lyons ML, Evans CL, Griffin JW, Hart JM, Miller MD, Brockmeier SF (2015) Arthroscopic suprapectoral and open subpectoral biceps tenodesis: a comparison of restoration of length-tension and mechanical strength between techniques. Arthroscopy 31(4):620–627